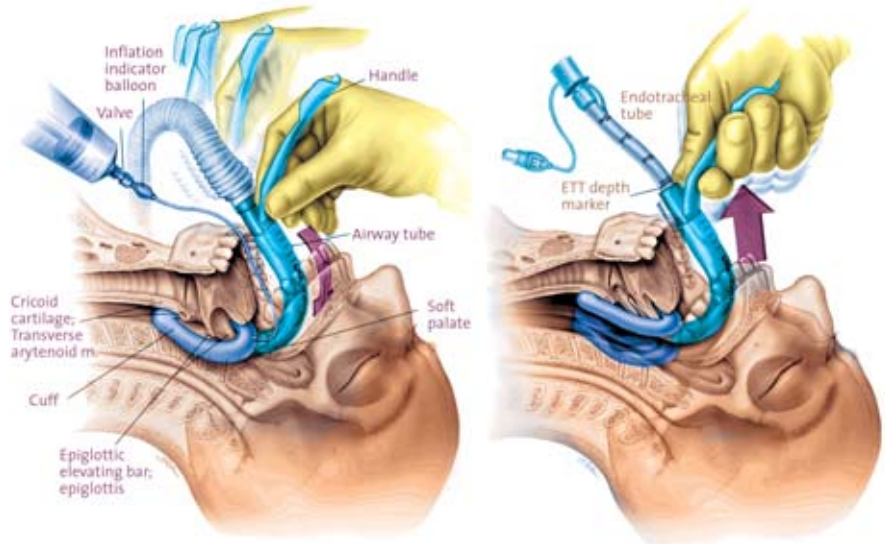




Laryngeal Mask Airway Devices: Three Maneuvers For Any Clinical Situation



CHANDY VERGHESE, MBBS, FRCA

Consultant in Anaesthesia and Intensive Care
Royal Berkshire NHS Foundation Trust
Reading, Berks, United Kingdom

Dr. Vergheese receives an annual honorarium from LMA Worldwide for training and research.

The Chandy maneuver.

Image courtesy of Lippincott Williams & Wilkins, reprinted with permission.

During the past 2 decades, the laryngeal mask airway (LMA; LMA North America) and its variants have proved to be safe, effective, and minimally invasive airways in a wide variety of surgical procedures for patients who have fasted. The 3 maneuvers described below, developed by clinicians with considerable expertise in the use of these products, can help practitioners optimize their skill with these devices.

The Up-Down Movement

Archibald Brain, MD, the inventor of the laryngeal mask airway (LMA), described the up-down movement of the device on numerous occasions. After the LMA has been inserted and the cuff inflated, the up-down movement is performed without deflating the cuff within the patient's mouth. This movement repositions a down-folded epiglottis and may be used with all currently available laryngeal mask airway devices when initial resistance to bag ventilation is encountered, and it may need to be repeated. The maneuver is most commonly

performed with the LMA Fastrach or CTrach. It involves gripping the handle of the device, swinging it outward about 6 cm, and reinserting it without deflating the cuff (the "cm" markings on the airway tube may be used as a guide). Liu et al found that the up-down maneuver improved the glottic view in 51 (90%) of 57 patients studied.¹ Goldman and Wender have visually confirmed this finding during use of the LMA CTrach.²

The Chandy Maneuver

This maneuver (above) was first described by the

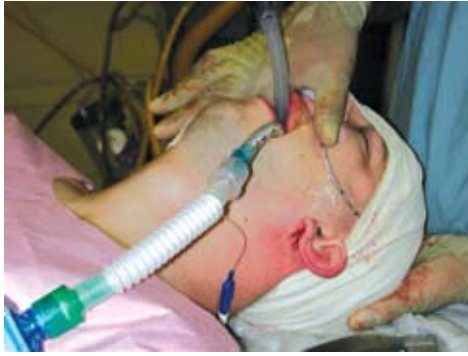

Figure 1. Bailey maneuver: insertion of an LMA Classic “behind” a tracheal tube, using the recommended technique.

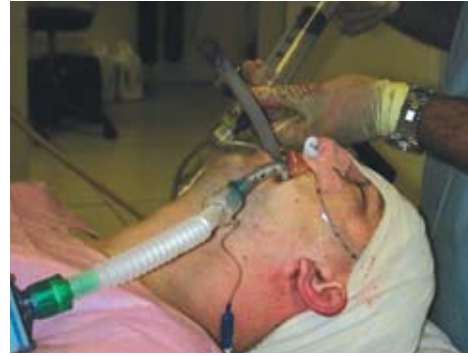

Figure 2. Bailey maneuver: inflation of the cuff of the LMA Classic prior to removing the tracheal tube.

Images courtesy of A. Patel, MBBS, Consultant Anesthetist, Royal National Throat, Nose and Ear Hospital, London.

author.³ The purpose is to optimize the success of “blind” tracheal intubation when using the LMA Fastrach. The maneuver consists of 2 sequential steps. Before the technique is performed, the expiratory valve of the breathing circuit should be partially closed to ensure high positive pressure within the breathing circuit. The metal handle is used to rotate the device in the sagittal and/or coronal planes to establish optimal ventilation with minimal resistance to bag ventilation and audible “leaks” during manual ventilation. In the optimal position, audible leakage of the gas mixture from the circuit will be minimal. The handle is held in this position and optimizes the passage of the tracheal tube. The second step is to use the handle to lift (but not tilt) the LMA Fastrach or CTrach away from the posterior pharyngeal wall. The first step enables optimal alignment of the laryngeal aperture and the bowl of the mask, and the second facilitates smooth passage of the dedicated endotracheal tube (ETT). Ferson et al reported that the incidence of multiple intubation attempts was significantly lower when the Chandy maneuver was used (4 [5%] of 73 cases vs 41 [32%] of 127 cases; odds ratio, 0.12; 95% confidence interval, 0.04-0.36 multiple attempts; $P=0.0001$).³

The second step also may be used to increase the “seal pressure” for positive pressure ventilation and may help protect the airway if regurgitation inadvertently occurs.⁴

The Bailey Maneuver

The exchange of an ETT for a laryngeal mask airway (any version) at the end of a long surgical procedure provides an excellent airway during emergence from anesthesia for a patient who has fasted. Paul Bailey, consultant anesthetist at the Royal National Throat, Nose and Ear Hospital in London, first recognized and

described this exchange (Figures 1 and 2).^{5,6} Toward the end of surgery, with the patient still under “deep” anesthesia and following oropharyngeal suction, a laryngeal mask device is inserted behind the ETT and its cuff inflated. The ETT cuff is deflated and the tube removed. The patient is ventilated through the mask airway. The mask airway is left in place until the patient regains consciousness and is able to remove the mask airway when prompted verbally. The laryngeal mask airway, when properly inserted (with a cuff pressure of 60 cm H₂O or less) provides a clear airway without desaturation, coughing, bucking, or straining, and with a minimal cardiovascular response that facilitates a smooth return to consciousness.^{7,8}

References

1. Liu EH, Goy RW, Chen FG. An evaluation of poor LMA CTrach view with fiberoptic laryngoscope and the effectiveness of corrective measures. *Br J Anaesth.* 2006;97(6):878-882.
2. Goldman AJ, Wender R. Evaluation of the fiberoptic LMA-CTrach after difficult laryngoscopy with failed intubation. *Anesthesiology.* 2006;105:A519.
3. Ferson DZ, Rosenblatt WH, Johansen MJ, Osborn I, Ovassapian A. Use of the intubating LMA-Fastrach in 254 patients with difficult-to-manage airways. *Anesthesiology.* 2001;95(5):1175-1181.
4. Verghese C, Rangasami J, Kapila A, Parke T. Airway control during percutaneous dilatational tracheostomy: pilot study with the intubating laryngeal mask airway. *Br J Anaesth.* 1998;81(4):608-609.
5. Williams PJ. Insertion technique for reinforced laryngeal mask airway and its use in recovery. *Anaesthesia.* 1993;48(8):733-734.
6. Nair I, Bailey PM. Review of uses of the laryngeal mask in ENT anaesthesia. *Anaesthesia.* 1995;50(10):898-900.
7. Koga K, Asai T, Vaughan RS, Latto IP. Respiratory complications associated with tracheal extubation. Timing of tracheal extubation and use of the laryngeal mask during emergence from anaesthesia. *Anaesthesia.* 1998;53(6):540-544.
8. Abdy S. An audit of airway problems in the recovery room. *Anaesthesia.* 1999;54(9):372-375.