

Rectal Foreign Bodies

Joel E. Goldberg, MD, FACS^{a,*}, Scott R. Steele, MD, FACS, FASCRS^b

KEYWORDS

- Rectal foreign bodies • Perforation
- Transanal approach • Endoscopy

Rectal foreign bodies often pose a challenging diagnostic and management dilemma that begins with the initial evaluation in the emergency department and continues through the postextraction period. Numerous objects ranging from billy clubs, varied fruits and vegetables, nails, light bulbs, and a turkey baster to a propane tank have been described as retained rectal foreign bodies. Because of the wide variety of objects and the variable trauma that can be caused to the local tissues of the rectum and distal colon, a systematic approach to the diagnosis and management of the retained rectal foreign body is essential. One of the most common problems encountered in the management of rectal foreign bodies is the delay in presentation, as many patients may be embarrassed and reluctant to seek medical care. Moreover, in the emergency room, patients may often be less than truthful regarding the reason for their visit, leading to extensive workups and further delays. Even after extraction, rectal foreign bodies can lead to delayed perforation or significant bleeding from the rectum. Hence, a stepwise approach to the diagnosis, removal, and postextraction evaluation is essential.

EPIDEMIOLOGY

Although retained rectal foreign bodies have been reported in patients of all ages, genders, and ethnicities, more than two-thirds of patients with rectal bodies are men in their 30s and 40s, and patients as old as 90 years were also reported.^{1–3} The literature is replete with single-center case studies because this is generally a rare problem that does not lend itself to a systematic or prospective analysis (**Table 1**). A report from one major teaching hospital spanning a 10-year period reported approximately 1 rectal foreign body per month.⁴ The incidence is even lower in smaller community-based hospitals.

^a Division of General and Gastrointestinal Surgery, Section of Colon and Rectal Surgery, Brigham and Women's Hospital, Harvard Medical School, 75 Francis Street, Boston, MA 02115, USA

^b Department of General Surgery, Colon and Rectal Surgery, Madigan Army Medical Center, Fort Lewis, WA 98431, USA

* Corresponding author.

E-mail address: jgoldberg1@partners.org (J.E. Goldberg).

Table 1
Rectal foreign body series

Author (Year)	Number of Patients	Male/ Female	Age (Mean or Median in y)	Insertion (Anal/ Ingestion)	Extraction (Transanal/ Abdominal)	Stoma (Number)	Morbidity/Mortality (Percentage)
Rodriguez (2007) ²	30	20/10	42.5	16/14	23/7	6	14/0
Clarke (2005) ³	13	13/0	45	13/0	8/5	2	NA
Lake (2004) ⁴	87	85/5	40	87/0	79/8	2	1/0
Ruiz (2001) ¹⁰	17	14/3	46.3	17/0	10/7	5	0/0
Biriukov (2000) ¹¹	112	111/1	16–80	112/0	107/6	NA	NA
Ooi (1998) ¹	30	25/5	46	30/0	27/3	1	7/0
Cohen (1996) ¹²	48	45/3	33.6	48/0	42/6	5	0/0
Yaman (1993) ¹³	29	28/1	42.5	22/7	27/2	2	17/0
Marti (1986) ¹⁴	8	NA	38	8	NA	NA	0/0
Nehme Kingsley (1985) ¹⁵	51	51/0	19–94	51/0	50/1	0	0/0
Barone (1983) ¹⁶	101	101/0	16–48	101/0	89/12	11	NA/1
Crass (1981) ¹⁷	29	26/3	10–84	29/0	15/14	10	14/3
Sohn (1977) ¹⁸	11	11/0	35	11/0	7/4	4	10/0
Barone (1976) ¹⁹	28	26/2	16–56	28/0	23/5	5	14

Abbreviation: NA, not available.

Data from Steele SR, Goldberg JE. Rectal foreign bodies. In: Basow DS, editor. UpToDate. Waltham (MA): UpToDate, Inc; 2009. For more information visit <http://www.uptodate.com>.

Data from Refs.^{1–4,10–19}

Table 2
AAST rectal organ injury scale

Grade I	Hematoma: contusion or hematoma without devascularization and/or partial-thickness laceration
Grade II	Laceration \leq 50% circumference
Grade III	Laceration $>$ 50% circumference
Grade IV	Full-thickness laceration with extension into the perineum
Grade V	Devascularized segment

Data from Moore EE, Cogbill TH, Malangoni MA, et al. Organ injury scaling, II: Pancreas, duodenum, small bowel, colon, and rectum. J Trauma 1990;30:1427.

CLASSIFICATION

Although the American Association for the Surgery of Trauma (AAST) rectal organ injury scale is generally used for blunt and penetrating trauma, its use for injury secondary to rectal foreign bodies is appropriate (**Table 2**). The treatment of all rectal injuries depends on the degree of injury, which is classified according to presence of hematoma, the percent circumference laceration, and whether or not there is devascularization of the rectum and perforation/extension into the perineum.⁵ Another useful classification of rectal foreign bodies has been to categorize them as voluntary versus involuntary and sexual versus nonsexual (**Table 3**). By far the most common category of rectal foreign bodies is objects that are inserted voluntarily and for sexual stimulation. Numerous objects have been described in the literature, and a partial listing from the literature and the authors' experience includes vibrators, dildos, a turkey baster, a Billie club, cucumbers, apples, light bulbs, Christmas ornaments, a camping stove, knives, trailer hitch, nails, bottles, utensils, and a pill bottle. Involuntary sexual foreign bodies are almost exclusively in the domain of rape and sexual assault. The most infamous case is that of Haitian immigrant Abner Louima who was assaulted by 4 New York City Police Department officers after a scuffle at a nightclub in Brooklyn, New York, in 1997. He was repeatedly sodomized with a broomstick handle, resulting in rectal and bladder injuries that required several operations and more than 2 months stay in the hospital.⁶ The second most common type of rectal foreign body is best known as body packing and is commonly used by drug traffickers. A person known as a mule swallows several packages of drugs (usually heroin or cocaine) wrapped in plastic bags and/or condoms. The potential complications from body packing include impaction, obstruction, perforation, and even rupture of

Table 3
Classification of rectal foreign bodies

Voluntary		Involuntary
Sexual	Vibrators, dildos, varied other objects	Rape or assault (ie, the Abner Louima case where New York City Police Department assaulted/sodomized him with a broom stick in 1997).
Nonsexual	Body packing of illicit drugs	The mentally ill or children: retained thermometers; enema tips; oral ingestion, such as bones, toothpicks, plastic objects

the packages resulting in systemic absorption of the drugs, which can result in overdose and even death of the mule.⁷ Involuntary nonsexual foreign bodies are generally found in the elderly, children, or the mentally ill. The objects are usually retained thermometers and enema tips; aluminum foil wrapping from pill containers; and orally ingested objects, such as tooth picks, chicken bones, plastic objects such as erasers or pill bottle caps, and even coins or small plastic toys. Any of these mechanisms or objects can cause severe injury. Therefore, all retained rectal foreign bodies should be treated as potentially hazardous. Despite the potential for severe injury, most rectal injuries from foreign bodies result in grade I or grade II injuries.

EVALUATION AND MANAGEMENT

History and Physical Examination

Patients with rectal foreign bodies are embarrassed and often reluctant to state the true nature of their emergency room visit. As a result, they may present with a chief complaint of rectal pain or abdominal pain, bright red blood per rectum, inability to have a bowel movement, and rectal mucous leakage. In most cases, patients present several hours to days after the placement of the rectal foreign body, and on occasion, the foreign body has even been successfully removed but the patient has delayed symptoms of bleeding, perforation, or even incontinence.^{1,4} When suspected, physicians need to bring up the possibility of a retained or removed rectal foreign body in a nonconfrontational way. This may be difficult, especially in the case of nonvoluntary placement, and physicians should also be prepared to provide emotional support. Yet, valuable information may be gained from a description of the object(s), timing of event, and history of repetitive trauma from either placement or attempted removal.

Physical examination of the patient with a rectal foreign body can present with a wide spectrum of findings. If the object is distal and no significant trauma is present, then the examination can be quite benign. But if there is perforation above the peritoneal reflection, the patient can present with frank peritonitis. Often, the rectal foreign body can be palpated in either the left or right lower quadrant of the abdomen. The rectal examination has similar variability to the abdominal examination. The foreign body may be palpable in the distal rectum or, if higher up, the surgeon may not be able to feel it on digital examination. Bright red blood per rectum is often seen but is not always present, and should not be interpreted as minimal injury potential when absent. Careful attention should also be paid to the status of the sphincter, especially in patients without a prior history of foreign body placement and in those nonvoluntary cases. In patients without sphincter injury, the rectal sphincter may have increased tone secondary to muscular spasm as a result of the foreign object. In other cases, the sphincter may have obvious damage with visible injury to both the internal and external sphincter. In either case, a careful examination and documentation of resting and squeeze tone and sensation is important.

Laboratory and Radiologic Evaluation

In general, laboratory evaluation is not very helpful in the patient with a rectal foreign body. If the patient has a suspected perforation, the white blood cell (WBC) count may be elevated and/or acidosis may be present on chemistry. However, these laboratory tests are not very helpful, as the physical examination will be more revealing as to the extent of injury. In select cases, elevated WBC count or acidosis may be suggestive of occult injuries, such as mucosal ischemia from pressure necrosis, or an extraperitoneal rectal perforation, both of which may not be immediately obvious on examination. Laboratory tests should be limited to those that are necessary in case an operation is

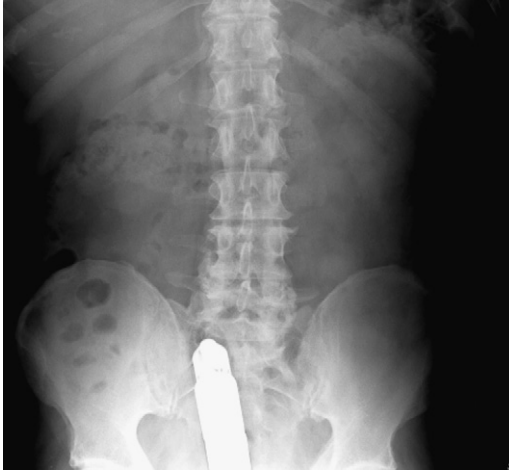

Fig. 1. Rectal dildo on abdominal plain film. (Courtesy of Joel Goldberg, MD, Boston, MA.)

needed. Hence, a clot in the blood bank and general chemistries that may be useful to the anesthesia provider should be ordered. Radiologic evaluation is far more important than any laboratory test. A flat and upright series of the abdomen will show the location of the object and the presence or absence of pneumoperitoneum (**Figs. 1 and 2**).

Management

The first step in the evaluation and management of a patient with a rectal foreign body is to determine whether or not a perforation occurred. When a perforation is suspected, it should be determined as soon as possible whether the patient is stable or unstable. The history and physical examination helps to determine if the patient has peritonitis, whereas the plain radiographs may help localize the object and rule out free air. These steps in conjunction with each other allow one to decide if the situation is a surgical

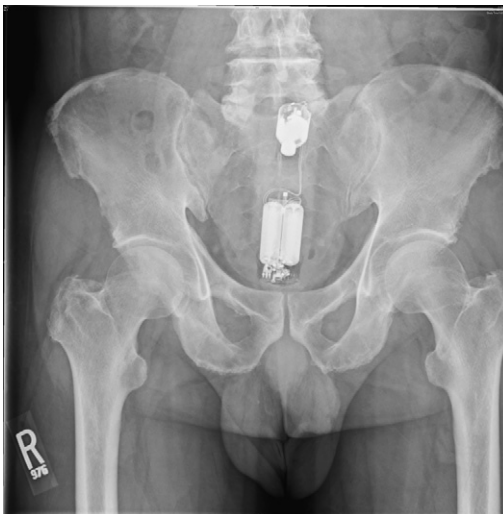

Fig. 2. Rectal vibrator on abdominal plain film. (Courtesy of Joel Goldberg, MD, Boston, MA.)

emergency or if a more measured approach can be taken. Hypotension, tachycardia, severe abdominopelvic pain, and fevers are indicative of a perforation. If there is free air or obvious peritonitis indicating a perforation, then the patient needs immediate resuscitation with intravenous fluids and broad-spectrum antibiotics. A Foley catheter and nasogastric tube should be placed, and appropriate blood samples should be sent to the laboratory for evaluation, including a complete blood count, chemistries, and a type and crossmatch. If the patient appears stable and has normal vital signs but a perforation is suspected, a computed tomographic (CT) scan often helps determine if there has been a rectal perforation (**Fig. 3**). This is often the case for perforations below the level of the peritoneal reflection. Rectal wall thickening, mesorectal air, fluid collections, and fat stranding are all indications of a full-thickness injury and should be considered as indicative until proved otherwise. When a foreign body is removed or absent in the rectal vault, rigid proctoscopy or endoscopic evaluation may reveal the rectal injury or the foreign body located higher in the rectosigmoid.

In clinically stable patients without evidence of perforation or peritonitis, the rectal foreign body should be removed either in the emergency department or in the operating room, if general anesthesia is needed. If the object is proximally located and the patient is stable, then a trial of nonoperative management and observation to see if the object passes more distally should be attempted. Although the use of stimulants and enemas has been described, their routine use has not been endorsed by most practitioners because there is the theoretical risk of causing more extensive rectal wall injury, perforation, or even possibly propelling the object more proximally in the colon. Many rectal foreign bodies fail to pass on their own and need to be extracted in either the emergency room or the operating room. Most objects can be removed transanally, and if not, then a transabdominal approach is used.⁴ The authors recommend direct visualization with rigid proctoscopy or flexible sigmoidoscopy for all patients after the object has been removed to evaluate the status of the rectum and rule out ischemia or wall perforation.

EXTRACTION TECHNIQUES

Transanal Approach

When attempting to remove a rectal foreign body transanally, the most important factor in successful extraction is patient relaxation. This can be achieved with a perianal nerve block, a spinal anesthetic, or either of these in combination with intravenous conscious sedation. All of these techniques allow the patient to relax, decrease anal

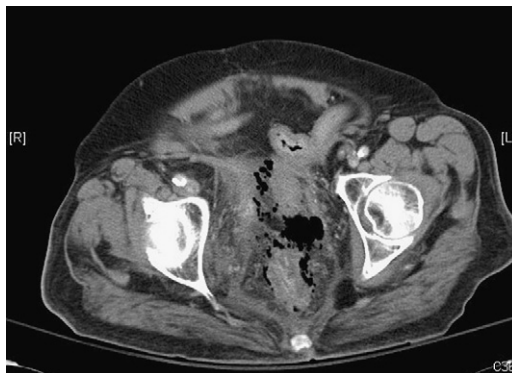

Fig. 3. Rectal perforation with extraperitoneal air seen on CT scan. (Courtesy of Joel Goldberg, MD, Boston, MA.)

sphincter spasm, and improve visualization and exposure. In general, a perianal nerve block similar to that used for anorectal surgery works quite well. The authors favor using lidocaine (Xylocaine) 1% with epinephrine and bupivacaine 0.5% with epinephrine in a 50:50 mix. A superficial block and then an intersphincteric block circumferentially around the anal verge are performed. Finally, a pudendal nerve block is performed. The branches of the pudendal nerve that innervate the anal sphincter complex approach the sphincter complex from a posterolateral location. A pudendal nerve block is done by infiltrating the tissues deeply in a fanlike technique approximately 1 cm medial to the ischial tuberosities in the posterolateral location bilaterally. Approximately 2 to 5 mL of the local anesthetic mix is used on each side.

Only after the patient has been appropriately sedated and anesthetized should attempts be made to remove the object. The high lithotomy position in candy cane stirrups facilitates removal of most objects and has the added benefit of allowing for downward abdominal pressure to aid in extraction of the foreign body. Although the size and location of the object may be determined by the preprocedure films, a digital rectal examination is the critical first step in evaluating the patient with a rectal foreign body, allowing the surgeon to see if the object is within reach of the anal verge. The anal canal should then be gently dilated to 3 fingers' breadth. If the foreign body can be easily palpated, it is amenable to transanal extraction using one of many clamps and instruments. If not easily grasped with a hand, the authors prefer to use a Kocher clamp or a ring forceps to take hold of the object and to bring it down to the anal verge where it can be grasped with the surgeon's hand and then be removed easily. After successful removal of a rectal foreign body, the mucosa of the colon and rectum needs to be examined. A rigid sigmoidoscopy is recommended, although some advocate a flexible sigmoidoscopy. The goal is to completely evaluate the mucosa of the distal colon and rectum to make sure that there is no active bleeding, additional foreign bodies, or full-thickness injury to the bowel mucosa. A repeat plain film of the abdomen is often warranted to ensure that no perforation took place during the extraction process. Because the surgeon will encounter various differing objects, there are many methods to be aware of that may aid in the removal of the foreign body, depending on its size and shape.

Blunt and Sharp Objects

The best method for the removal of a blunt object is to grasp the object using one of the clamps mentioned earlier or, better yet, using the surgeon's hand, depending on the laxity of the anal canal and the success of the anal block. If the patient has a lax anal sphincter, there is a good block, and the patient is adequately sedated, then the object is often easily removed. Frequently, the patient can be asked to perform the Valsalva maneuver to see if that maneuver helps propel the object closer to the anal canal. Smooth objects, such as bottles, fruits and vegetables, dildos, and vibrators, cannot always be grasped, and caution should be taken to ensure that they are not broken inside the patient. In the cases of fruits and vegetables, however, either grasping or breaking apart the object is a well-described technique that aids in the removal of the foreign body. Some smooth foreign bodies create a seal with the rectal mucosa. When downward traction is placed on the object, a vacuum force is created that prevents the removal of the object. In this case, it has been shown that placing a Foley catheter alongside the object and inflating the balloon above it helps in extraction in 2 ways. First, once the balloon is inflated above the object, air can be insufflated and the suction vacuum seal is broken. The balloon is then left inflated and is used to pull the object down toward the rectum. In the case of a jar, a larger ballooned implement (Sengstaken-Blakemore or Minnesota tube) can be inserted into the jar and the

balloon can be inflated inside the jar and thereby can be used to extract the jar. Obstetric vacuum extractors have even been described to grasp the object, widen the canal, and release the rectal seal.^{1-4,8-19} Removal of sharp objects can prove even more difficult, as they pose an additional risk for both the patient and the surgeon. These objects should be removed with the utmost care under direct visualization through a rigid or flexible endoscope. Once again, the rectal mucosa must be closely examined for tears, bleeding, and perforation.

Body Packers

The ingestion of illicit drugs in small packets poses a particularly challenging dilemma as the surgeon has to balance extracting the foreign object with using too much force that could result in the rupture of the packets. Most body packers use condoms that are filled with drugs and then swallowed (**Fig. 4**). Clamps are not recommended when attempting to remove these, as the packets are easily ruptured. If the packets are not within reach of the surgeon's hand and there is no systemic toxicity, the patient should be admitted and observed and the packets will eventually pass to a point where the surgeon can remove them manually. Should signs or symptoms of perforation or drug ingestion/toxicity be observed, then exploratory laparotomy for removal of the remaining packets and aggressive medical treatment for the overdose is warranted.

Endoscopy

Flexible endoscopy is reserved for objects that are located more proximally in the rectum or the distal sigmoid colon. Endoscopy also provides excellent visualization of the mucosa to evaluate for subtle and gross changes in the rectal mucosa. Lake and colleagues⁴ reported on the location of the foreign body and need for surgery.

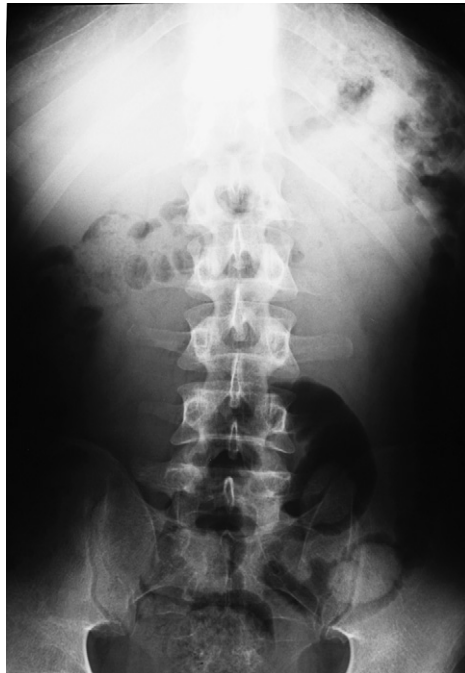

Fig. 4. Body packing with sigmoid colon condoms seen on plain films. (Courtesy of Koenraad Morteale, MD, Boston, MA.)

When the object was present in the sigmoid colon, 55% of cases required surgery, whereas only 24% required surgery when the object was present in the rectum. Endoscopy can serve as a middle ground in many cases to avoid surgical exploration by enabling evaluation and therapeutic removal of objects that may have been nonamenable to transanal extraction. Once the object is identified with the flexible endoscope, it can be grasped with a polypectomy snare, much like using a lasso (**Fig. 5**). The scope can also be used to place air in the vault, breaking the seal much like the Foley catheter. Once successful extraction has been accomplished, the endoscope should be passed again to evaluate the bowel mucosa for any inadvertent injuries.

Surgery

If the local perianal block and sedation are unsuccessful in the emergency department, the patient needs to be brought to the operating room for a general or spinal anesthetic to aid in the removal of the object. In many cases, even deeper conscious sedation is successful to provide the relaxation needed to aid in removal. Once again, downward pressure on the object in the left iliac fossa greatly aids in moving the object toward the rectum and stabilizing it when attempting to grab it from below. After anesthesia has been applied and the patient is adequately relaxed, if the foreign body cannot be removed from below then a laparotomy is indicated. Surgery is also indicated in all patients who present with perforation (free air), sepsis, or peritonitis. Some surgeons have also described laparoscopy as an aid to push the object more distally into the rectum for a transanal removal.^{20,21} In the absence of a perforation,

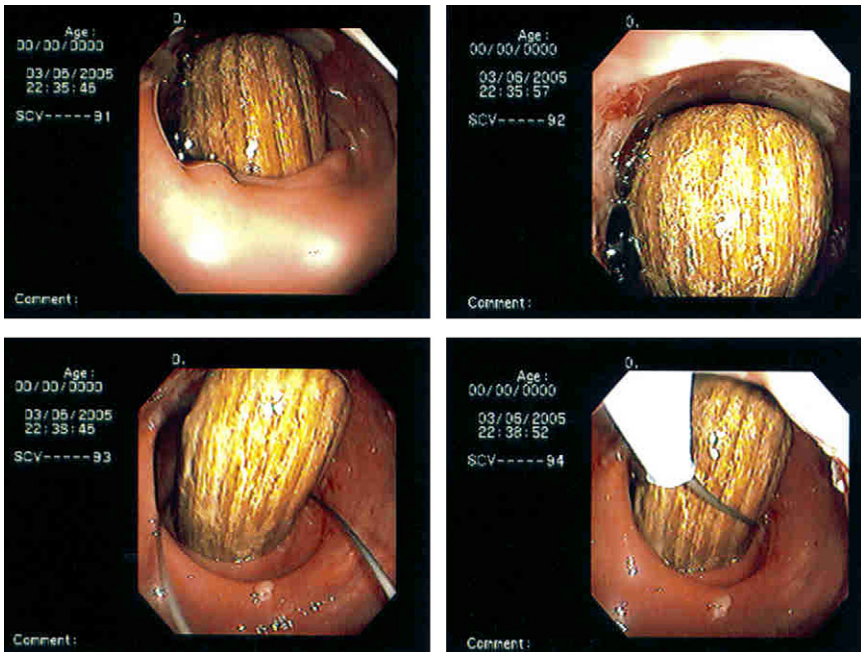


Fig. 5. Rectal billy club and endoscopic extraction with colonoscopy snare. (Courtesy of Justin Maykel, MD, Worcester, MA. Reproduced from Steele SR, Goldberg JE. Rectal foreign bodies. In: Basow DS, editor. UpToDate. Waltham (MA): UpToDate, Inc; 2009; with permission. For more information visit <http://www.uptodate.com>.)

once inside the abdomen, the first step is to attempt to milk the object distally into the rectum. If this fails, then a colotomy and removal of the foreign object is needed. This colotomy can be primarily repaired and often no diversion is needed. Diversion is reserved for patients with frank peritonitis and instability, perforation with extensive fecal contamination, and proper surgical judgment. After removal of the object, the entire length of the bowel needs to be inspected to make sure there are no inadvertent injuries.

POSTREMOVAL MANAGEMENT AND COMPLICATIONS

The most dangerous complication of a rectal foreign body is perforation. When patients present with a rectal perforation, they should at first be stabilized like any trauma patient. After stabilization, management depends on 3 factors: first, whether the patient is clinically stable or unstable, second, whether the perforation is in an intraperitoneal or extraperitoneal location, and last, whether there is significant fecal soilage or not. A good rule of thumb is to manage a rectal perforation from a foreign body in the same way as a colorectal bullet or stab wound. The historical principles of treating a rectal injury are diversion, debridement, distal washout, and drainage (4 "D's"). Each of these procedures depends on the degree of contamination, the amount of time since the perforation, and the extent and location of the injury. Clearly, the surgeon needs to individualize the care of these patients. The trauma literature has shown that primary repair with and without diversion for intraperitoneal injuries is acceptable and depends on the principles outlined earlier.^{22,23} Unstable patients, those with multiple comorbidities, and those with significant tissue damage and delayed presentation more often require a diversion. On the other hand, patients who present early after the insult, those with minimal tissue damage, and those with little to no contamination can be managed with primary repair and washout. Small extraperitoneal injuries can also be managed with observation, avoidance of oral feeding, and antibiotics. After several days, a gentle diatrizoate (Gastrografin) enema should be performed to see if the perforation has healed.²⁴ Like the trauma literature, the 4 "D's" of rectal trauma management are highly controversial as to which, if any, are required. The authors recommend consideration for each component, with individualization as per surgeon experience, judgment, and comfort level.

Postremoval observation depends on several factors, such as the clinical status of the patient, comorbidities, delay in presentation, and whether or not there was any resultant trauma to the rectum or surrounding tissue. Postextraction endoscopy and plain radiographs are a must before discharging any patient who had a foreign body removal. Even with routine transanal extraction, the authors recommend several hours of close observation with serial abdominal examinations and plain films as indicated. Major complications from rectal foreign bodies are rare, but can be life threatening if missed. Bleeding from lacerations in the rectal mucosa are generally self-limited but can on occasion require repeat examination under anesthesia and suture ligation. Perforation can result in a laparotomy and even a colostomy, which then requires a repeat operation for colostomy reversal. Death from sepsis and multisystem organ failure has been reported.²⁵ If a major laparotomy is performed, the patient is also at risk for cardiovascular morbidity and wound complications (ie, infection and hernia). In addition, traumatic disruption of the anal sphincter can result in mild to severe fecal incontinence, depending on the degree of the injury.²⁶ Attempts for surgical correction of any sphincter injury should be delayed until adequate time has passed to evaluate any resultant defect and clinical symptoms.

After a foreign body incident, and especially with sexual assault, patients will often experience a wide range of emotions from shock, disbelief, denial, embarrassment, and guilt to flashbacks, fear, anger, and stress. Long-term consequences may occur, such as substance abuse or psychological problems. As such, the authors recommend offering all patients counseling by an experienced mental health care provider.

SUMMARY

Rectal foreign bodies present a difficult diagnostic and management dilemma. This is often because of the delayed presentation, wide variety of objects that cause the damage, and the wide spectrum of injury patterns that range from minimal extraperitoneal mucosal injury to free intraperitoneal perforation, sepsis, and even death. The evaluation of the patient with a rectal foreign body needs to progress in an orderly fashion, with appropriate examination, laboratory and radiographic evaluation, and resuscitation with intravenous fluids and antibiotics. In the nonperforated stable patient, the object should be removed in the emergency department with a local block and/or conscious sedation via the transanal approach. If this fails, then the patient should go to the operating room for a deeper anesthetic and attempt at transanal extraction. Surgery with a laparotomy should be reserved for patients with perforation or ischemic bowel or cases of failed transanal attempts. Colostomy is not mandatory in all patients, with care being based on their overall condition, length of time since perforation, comorbidities, concomitant injuries, and surgical judgment. After removal of the foreign body, the authors suggest a period of observation, a rigid or flexible endoscopy to evaluate for rectal injury, and repeat plain films to examine for evidence of injury and perforation that may have occurred during the extraction process.

REFERENCES

1. Ooi BS, Ho YH, Eu KW, et al. Management of anorectal foreign bodies: a cause of obscure anal pain. *Aust N Z J Surg* 1998;68:852.
2. Rodriguez-Hermosa JI, Codina-Cazador A, Ruiz B, et al. Management of foreign bodies in the rectum. *Colorectal Dis* 2007;9:543.
3. Clarke DL, Buccimazza I, Anderson FA, et al. Colorectal foreign bodies. *Colorectal Dis* 2005;7:98.
4. Lake JP, Essani R, Petrone P, et al. Management of retained colorectal foreign bodies: predictors of operative intervention. *Dis Colon Rectum* 2004;47:1694.
5. Moore EE, Cogbill TH, Malangoni MA, et al. Organ injury scaling, II: pancreas, duodenum, small bowel, colon, and rectum. *J Trauma* 1990;30:1427.
6. Brenner Marie. Incident in the 70th precinct. *Vanity Fair*; December 1997.
7. Traub SJ, Hoffman RS, Nelson LS. Body packing—the internal concealment of illicit drugs. *N Engl J Med* 2003;349:2519.
8. Johnson SO, Hartranft TH. Nonsurgical removal of a rectal foreign body using a vacuum extractor. Report of a case. *Dis Colon Rectum* 1996;39:935.
9. Feigelson S, Maun D, Silverberg D, et al. Removal of a large spherical foreign object from the rectum using an obstetric vacuum device: a case report. *Am Surg* 2007;73:304.
10. Ruiz de Castillo J, Selles Dechent R, Millan Scheiding M, et al. Colorectal trauma caused by foreign bodies introduced during sexual activity: diagnosis and management. *Rev Esp Enferm Dig* 2001;93:631.
11. Biriukov IuV, Volkov OV, An VK, et al. [Treatment of patients with foreign bodies in rectum]. *Khirurgiia (Mosk)* 2000;7:41 [in Russian].

12. Cohen JS, Sackier JM. Management of colorectal foreign bodies. *J R Coll Surg Edinb* 1996;41:312.
13. Yaman M, Deitel M, Burul CJ, et al. Foreign bodies in the rectum. *Can J Surg* 1993;36:173.
14. Marti MC, Morel P, Rohner A. Traumatic lesions of the rectum. *Int J Colorectal Dis* 1986;1:152.
15. Nehme Kingsley A, Abcarian H. Colorectal foreign bodies. Management update. *Dis Colon Rectum* 1985;28:941.
16. Barone JE, Yee J, Nealon TF Jr. Management of foreign bodies and trauma of the rectum. *Surg Gynecol Obstet* 1983;156:453.
17. Crass RA, Tranbaugh RF, Kudsk KA, et al. Colorectal foreign bodies and perforation. *Am J Surg* 1981;142:85.
18. Sohn N, Weinstein MA, Gonchar J. Social injuries of the rectum. *Am J Surg* 1977;134:611.
19. Barone JE, Sohn N, Nealon TF Jr. Perforations and foreign bodies of the rectum: report of 28 cases. *Ann Surg* 1976;184:601.
20. Berghoff KR, Franklin ME Jr. Laparoscopic-assisted rectal foreign body removal: report of a case. *Dis Colon Rectum* 2005;48:1975.
21. Rispoli G, Esposito C, Monachese TD, et al. Removal of a foreign body from the distal colon using a combined laparoscopic and endoanal approach: report of a case. *Dis Colon Rectum* 2000;43:1632.
22. Demetriades D, Murray JA, Chan L, et al. Penetrating colon injuries requiring resection: diversion or primary anastomosis? An AAST prospective multicenter trial. *J Trauma* 2001;50:765.
23. Herr MW, Gagliano RA. Historical perspective and current management of colonic and intraperitoneal rectal trauma. *Curr Surg* 2005;62:187.
24. Fry RD, Shemesh EI, Kodner IJ, et al. Perforation of the rectum and sigmoid colon during barium-enema examination. Management and prevention. *Dis Colon Rectum* 1989;32:759.
25. Waraich NG, Hudson JS, Iftikhar SY. Vibrator-induced fatal rectal perforation. *N Z Med J* 2007;120:U2685.
26. Madiba TE, Moodley MM. Anal sphincter reconstruction for incontinence due to non-obstetric sphincter damage. *East Afr Med J* 2003;80:585.